SCIENCE HUB REVIEW
2026
Volume 1
Issue 3
www.sciencehubreview.uz
ILMIY ELEKTRON JURNAL

OSTEOSARCOMA: CURRENT CONCEPTS AND EVOLUTIONS IN MANAGEMENT PRINCIPLES

Qobilov Odil Rustamovich[1]
Abdurakhimova Dildora Dilshod qizi[2]

[1] PhD, Associate professor of Department of Oncology, Oncohematology and Radiation oncology. Tashkent State Medical University, Tashkent, Uzbekistan. odqobilov776@mail.com 0009-0008-3190-3858
[2] 2nd Year master's student, Department of Oncology, Oncogematology and Radiation Oncology Tashkent State Medical University, Tashkent, Uzbekistan. abduraximovadildora3009@gmail.com orcid.org/0009-0001-9307-313

Abstract
Osteosarcoma is a rare malignancy arising from mesenchymal tissue, and represents the most common bone sarcoma. The management of osteosarcoma is challenging, and requires a multidisciplinary approach. In daily clinical practice, surgery, radiotherapy, and conventional chemotherapy constitute the therapeutic armamentarium against the disease. However, a significant number of patients with initially localized osteosarcoma will experience local or distant recurrence, and the prognosis for metastatic disease remains dismal. There is a pressing need to identify novel therapeutic strategies to better manage osteosarcoma and improve survival outcomes. In this study, we present recent advances in the therapeutic management of osteosarcoma, including surgical and medical advances. The role of immunotherapy (immune checkpoint inhibitors, adoptive cellular therapy, cancer vaccines) and other targeted therapies including tyrosine kinase inhibitors is discussed; however, additional studies are required to delineate their roles in clinical practice.

Keywords
osteosarcoma; chemotherapy; targeted therapy; immunotherapy; immune checkpoint inhibitors; adoptive cellular therapy limb salvage therapy

1. Introduction

Osteosarcoma is a rare malignancy of mesenchymal origins, which is characterized by the production of osteoid from the neoplastic cells [1,2]. It is the most common bone

sarcoma, with an estimated incidence in Europe of 0.3/100,000/year [3]. The incidence of osteosarcoma demonstrates a bimodal age distribution, with an initial peak in adolescence (0.8–1.1/100,000/year in the age group of 15–19 years) that coincides with the pubertal growth spurt; a second peak in the seventh and eighth decades of life often represents a secondary malignancy, or is related to Paget disease [3,4]. Approximately two-thirds of the primary tumors are located around the knee joint, with the most common locations being the distal femur, the proximal tibia, and the proximal humerus [5,6]. The diagnosis of osteosarcoma relies on morphological characteristics, since specific molecular testing is not yet available in clinical practice [3]. According to the latest World Health Organization (WHO) classification, high grade osteosarcoma subtypes include conventional osteosarcoma, which is the most common subtype, telangiectatic osteosarcoma, and small cell osteosarcoma [7]. Periosteal osteosarcoma, which is predominantly chondroblastic, is an intermediate-grade osteosarcoma, whilst low-grade central osteosarcoma and parosteal osteosarcoma are reported as low-grade neoplasms. Both the diagnosis and management of osteosarcoma are challenging, and require a multidisciplinary approach. Currently, surgical excision, radiotherapy, and multiagent systematic therapy constitute the armamentarium of therapies against osteosarcoma in daily clinical practice [3]. However, it has been reported that 30–40% of patients with local osteosarcoma will eventually experience local or distant recurrence, with the 5-year overall survival for recurrent disease being 23–29% [8,9]. Furthermore, 10–20% of patients originally present with macroscopic metastatic disease, whilst the lungs are the most common site of metastases [5,8]. Given the high rate of relapse and the poor prognosis of metastatic disease, there is a pressing need to identify novel therapeutic approaches and biomarkers to better manage the disease. In the era of precision medicine, several efforts have been made to better understand the complex biology, genetic, and molecular background of osteosarcoma, and to develop new targeted therapies [6].

2. Current Therapeutic Approaches

The standard of care for localized low-grade osteosarcoma, such as low-grade central osteosarcoma and parosteal osteosarcoma, involves the surgical excision of the tumor with clear margins (R0 resection) [3]. As for localized periosteal osteosarcomas,

neoadjuvant or adjuvant chemotherapy is not recommended, since there is no solid evidence of benefit from its use [3,10]. In contrast, for localized high-grade osteosarcoma, curative intent treatment requires neoadjuvant multiagent chemotherapy, followed by surgical excision and adjuvant chemotherapy. The incorporation of chemotherapy for the therapeutic management of localized high-grade osteosarcoma was established in the 1980s, and has improved the disease-free survival probability from 60% [3,6]. First-line multiagent chemotherapy comprises doxorubicin, cisplatin, and high-dose methotrexate (MAP regimen) [3]. The histological response to neo-adjuvant therapy with MAP is evaluated post-surgery; however, changing the chemotherapy regimen based on this information has not been proven to improve outcomes [11,12]. Specifically, EURAMOS-1, a phase III, open-label, randomized, controlled clinical trial, investigated the addition of pegylated interferon alfa-2b (IFN-a-2b) to the MAP regimen in patients who responded to neo-adjuvant therapy (<10% viable tumor); meanwhile, in poor responders (≥10% viable tumor), the addition of ifosfamide and etoposide to MAP (MAPIE) was investigated. The results showed no improvement in event-free survival (primary end point) compared to patients who were treated with adjuvant MAP [11,12]. Furthermore, radiotherapy is indicated in selected cases where surgical resection of the tumor is not feasible, or the risk of local recurrence is high and additional surgery cannot be applied [3].

3. Advances in Targeted Therapies for Osteosarcoma

3.1. Clinical Experience of Immunotherapy Approaches in Osteosarcoma

Immunotherapy, a rapidly evolving area in oncology, has been applied with success in several malignancies including melanoma [14], non-small cell lung cancer [15,16], and renal cell carcinoma [17]. Novel immunotherapy approaches, including immunomodulating antibodies, adoptive cellular therapy, and cancer vaccines, have been investigated in several clinical studies that enrolled patients with different types of sarcomas, including osteosarcoma [18–21]. Selected clinical studies which have evaluated different types of immunotherapies in patients with osteosarcoma are presented in Table 1.

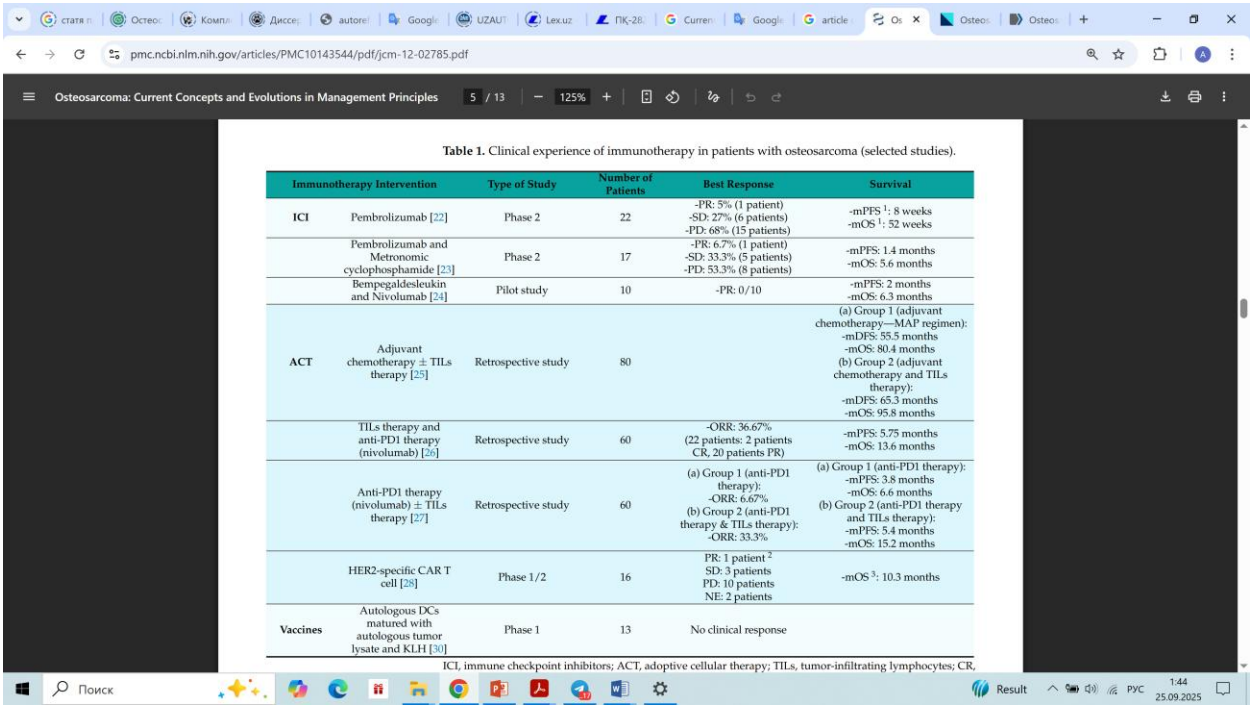

Table 1. Clinical experience of immunotherapy in patients with osteosarcoma (selected studies).

Immunotherapy Intervention		Type of Study	Number of Patients	Best Response	Survival
ICI	Pembrolizumab [22]	Phase 2	22	-PR: 5% (1 patient) -SD: 27% (6 patients) -PD: 68% (15 patients)	-mPFS [1]: 8 weeks -mOS [1]: 52 weeks
	Pembrolizumab and Metronomic cyclophosphamide [23]	Phase 2	17	-PR: 6.7% (1 patient) -SD: 33.3% (5 patients) -PD: 53.3% (8 patients)	-mPFS: 1.4 months -mOS: 5.6 months
	Bempegaldesleukin and Nivolumab [24]	Pilot study	10	-PR: 0/10	-mPFS: 2 months -mOS: 6.3 months
ACT	Adjuvant chemotherapy ± TILs therapy [25]	Retrospective study	80		(a) Group 1 (adjuvant chemotherapy—MAP regimen): -mDFS: 55.5 months -mOS: 80.4 months (b) Group 2 (adjuvant chemotherapy and TILs therapy): -mDFS: 65.3 months -mOS: 95.8 months
	TILs therapy and anti-PD1 therapy (nivolumab) [26]	Retrospective study	60	-ORR: 36.67% (22 patients: 2 patients CR, 20 patients PR)	-mPFS: 5.75 months -mOS: 13.6 months
	Anti-PD1 therapy (nivolumab) ± TILs therapy [27]	Retrospective study	60	(a) Group 1 (anti-PD1 therapy): -ORR: 6.67% (b) Group 2 (anti-PD1 therapy & TILs therapy): -ORR: 33.3%	(a) Group 1 (anti-PD1 therapy): -mPFS: 3.8 months -mOS: 6.6 months (b) Group 2 (anti-PD1 therapy and TILs therapy): -mPFS: 5.4 months -mOS: 15.2 months
	HER2-specific CAR T cell [28]	Phase 1/2	16	PR: 1 patient [2] SD: 3 patients PD: 10 patients NE: 2 patients	-mOS [3]: 10.3 months
Vaccines	Autologous DCs matured with autologous tumor lysate and KLH [30]	Phase 1	13	No clinical response	

ICI, immune checkpoint inhibitors; ACT, adoptive cellular therapy; TILs, tumor-infiltrating lymphocytes; CR,

Immune checkpoint inhibitors have been evaluated in patients with osteosarcoma, as a single agent therapy or in combination with chemotherapy, with disappointing results [22–24]. The SARC028, a phase 2, non-randomized, open-label, single-arm, multicenter, two-cohort clinical trial, investigated the single agent pembrolizumab (200 mg IV every 3 weeks) in patients with advanced soft tissue sarcoma and bone sarcoma [22]. With regards the bone sarcoma arm, 40 patients were evaluable for response, 22 of which were diagnosed with osteosarcomas, 13 with Ewing sarcoma, and 5 with chondrosarcoma. The primary end point was the objective response rate (ORR) by RECIST 1.1 criteria, which was 5% for bone sarcoma with a 43-week median duration of response. Among the patients who were diagnosed with osteosarcomas, 1 experienced a partial response (PR), 6 had stable disease (SD), and 15 experienced progression of the disease (PD). The median progression-free survival (PFS) and the median overall survival (OS) for the bone sarcoma arm were 8 weeks (95% CI 7–9) and 52 weeks (95% CI 40–72), respectively. Combinations of immune checkpoint inhibitors with chemotherapy have been investigated in patients with osteosarcomas as well. The PEMBROSARC clinical trial, a phase 2, multicenter, open-label study, explored a combination of pembrolizumab (200 mg IV every three weeks) with cyclophosphamide (50 mg twice daily; one week on followed by one week off) [23]. Seventeen patients with metastatic and/or unresectable osteosarcomas were enrolled in one of its strata, 15 of which were evaluable for efficacy.

The primary end points were determined as the non-progression and objective responses at 6 months, as per the RECIST 1.1 criteria. Specifically, the 6-month non-progression rate was 13.3%. The results showed that one patient (6.7%) experienced PR, 5 patients (33.3%) had SD, and 8 patients (53.3%) had PD. The median PFS and the median OS were 1.4 months (95% CI = 1.0 months– 1.4 months) and 5.6 months (95% CI = 2.1 months–12.1 months), respectively. Additionally, 14 patients were tested for PD-L1 expression, and only 2 were positive; interestingly, the one who experienced a PR did not express PD-L1. Adoptive cellular therapy, an innovative immunotherapeutic approach, has been evaluated in osteosarcomas, with encouraging results.

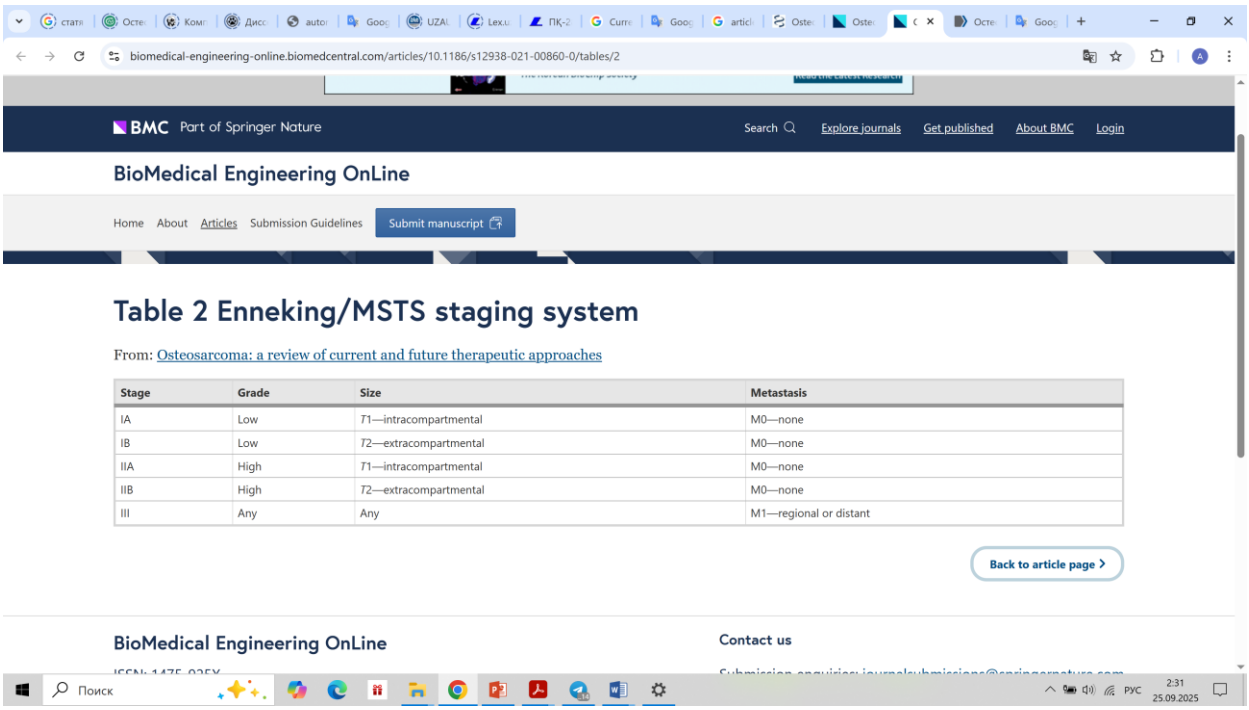

In 2020, Shi J. et al. published the results of a retrospective study that explored the efficacy of adjuvant chemotherapy in combination with tumor-infiltrating lymphocytes (TILs) treatment in patients with primary high-grade intramedullary osteosarcoma who had previously received neoadjuvant chemotherapy and had poor response, as proven histologically [25]. In total, 80 patients were included in the study; 40 patients (group 1) were treated with adjuvant chemotherapy, and 40 patients (group 2) received adjuvant chemotherapy in combination with TILs therapy.

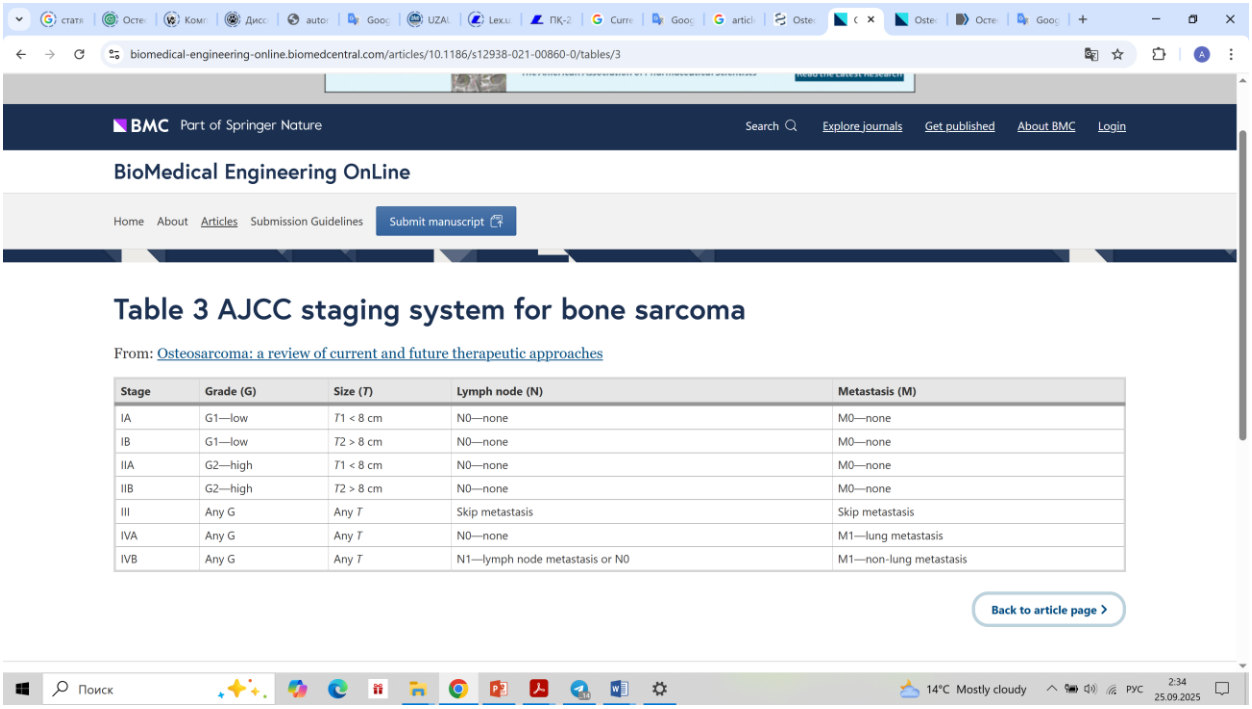

In both groups, neoadjuvant and adjuvant chemotherapy comprised the MAP regimen. The median disease-free survival (DFS) and median OS were estimated for both groups. For group 1, the median DFS was 55.5 months, and the median OS was 80.4 months; for group 2, the median DFS was 65.3 months and the median OS was 95.8 months. Several factors were examined as potential prognostic factors; interestingly, a greater number of transfused TILs were proposed as a potential prognostic factor, which is associated with increased median PFS and OS in osteosarcomas treated with adjuvant chemotherapy and TILs therapy.

3.2. Clinical Experience of Antibody-Drug Conjucates in Osteosarcomas

An antibody–drug conjugate (ADC) is an antibody that targets a specific cell surface protein linked with a cytotoxic agent [6,32]. ADCs are a promising class of therapeutics, especially for tumors which lack oncogenic ‘driver’ pathways [32]. Proteins that are overexpressed on osteosarcoma cells, such as the glycoprotein non-metastatic B (GPNMB), the leucine-rich repeat-containing 15 (LRRC15), B7-H3, GD2, and HER2, could represent potential targets for ADCs [6]. However, the clinical application of this therapeutic approach remains limited, and the results are conflicting. In 2019, Kopp L.M. et al. reported a single-arm phase 2 clinical trial which explored the anti-tumor activity of glembatumumab vedotin (an ADC against GPNMB) in patients with recurrent or refractory osteosarcoma [33]. Twenty-two adolescents and young adults were enrolled in

the study, and were treated with a 1.9 mg/kg/dose of glembatumumab vedotin on day 1 of a 21-day cycle. Disease control at 4 months and RECIST response was the primary end point. Limited clinical activity of glembatumumab vedotin in osteosarcoma patients was demonstrated. Specifically, 1 patient had a PR (4.5%), and 2 SD (9.1%). No correlation between GPNMB expression and response to glembatumumab vedotin was

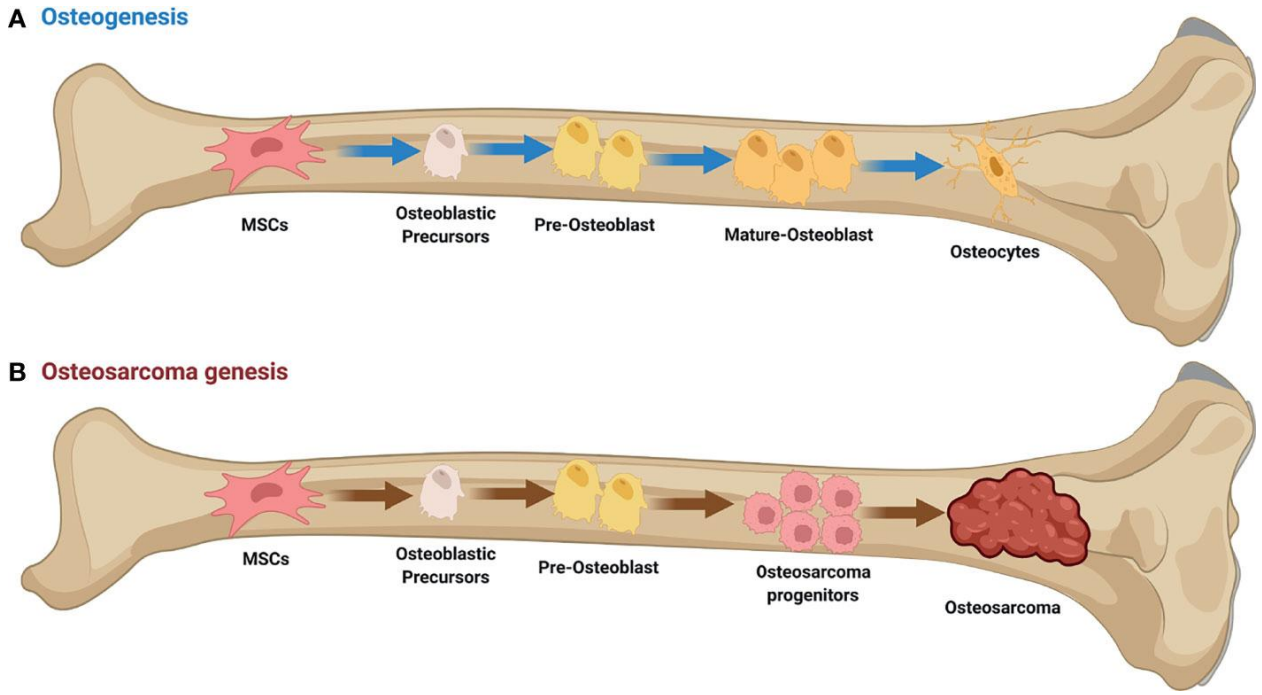

3.3. Clinical Experience of Tyrosine Kinase Inhibitors (TKIs) and beyond in Osteosarcomas

In recent years, efforts have been made towards the identification of driving molecular and genetic alterations in osteosarcomas, which could be used as potential targets for the management of osteosarcoma [35]. Multi-target TKIs have been tested in several clinical trials that included patients with osteosarcomas. A few TKIs, including sorafenib, regorafenib, cabozantinib, and apatinib, demonstrated promising results, encouraging their further investigation as single therapies or in combination with other agents; their toxicity remains a concern in this case. However, it is still unclear which TKI targets demonstrate a key role for osteosarcoma therapy [36].

4. Surgical Advances in the Management of Osteosarcoma

Whilst the judicious use of systemic oncological treatments has successfully improved the prognosis of patients with osteosarcoma, this therapy must be combined with appropriate local control in order to achieve a cure [57]. The surgical management of

osteosarcoma will vary depending on the site and characteristics of the tumor, but the overall goal is to achieve complete resection with wide margins (R0). This involves removing the tumor as well as a layer of normal surrounding tissue. This is vitally important, as studies have shown an increased risk of local recurrence and decreased survival with positive or "marginal" margins [58]. Surgery can be offered to patients with localized osteosarcomas and to patients with metastatic disease, provided that all sites are resectable. Osteosarcoma can present in surgically challenging areas of the body, such as the pelvis, base of the skull, spine, and jaw, all of which may require specialist input from additional specialties such as neuro, spinal, general, ENT and maxillofacial surgeons.



4.1. Preoperative Imaging and Planning

As part of staging and oncological work up, a variety of different imaging modalities are used to characterize tumors. The current guidelines for osteosarcoma management recommend that each patient should have a plain radiograph, magnetic resonance imaging (MRI), computerized tomography (CT), and, in certain cases, a positron emission tomography (PET) combined with a CT scan. Where surgical planning is concerned, MRI scans have been shown to provide accurate depictions of tumor appearances, including their limits within and outside the bone, differentiating medullary disease involvement, as well as soft tissue involvement [60,61]. Resection margins can be accurately measured

from high-resolution MRI scans, which can predictably inform the surgeon if a planned margin will be clear or affected by tumors. Studies have shown that MRI margin measurements with the closest predicted margin provided the smallest differences with pathology reports [62]. Although there is controversy in the literature with no defined 'safe' margin, it is generally accepted that a minimum soft tissue margin of >2 mm and a bony margin of >3 cm are required. The 'barrier effects' concept, introduced by Kawaguchi, further helps surgeon better plan and understand resection margins. This concept classified anatomical structures that provided resistance against tumor invasion (such as fascia, tendons, joint capsules, etc.) into thick (3–5 cm) and thin barriers (2 cm). Therefore, barrier effects can be considered to translate into distance equivalents; this means that at sites where barriers exist, surgeons can resect less of a margin than the true physical distance, allowing for more limb salvage options

5. Conclusions

Osteosarcoma is a rare malignancy of mesenchymal origins, and its diagnosis depends on morphological characteristics rather than molecular characteristics. The multifaceted nature of osteosarcoma tumors poses a unique challenge for both surgeons and oncologists. The high risk of recurrence with inadequate margins, close proximity to critical structures, and large anatomical variances coupled with the lack of large-scale research, add to the complexity of osteosarcoma surgery. Advances in medical technologies, as well as an appreciation for tailored and individualized patient treatment, have allowed surgeons to vastly improve outcomes with a number of developments. On the other hand, prognoses for patients with metastatic disease remains dismal, and new systematic therapy approaches are being explored. Immunotherapy has been investigated without major breakthroughs being reported to date, whilst certain TKIs have demonstrated early clinical benefits that provide new therapeutic options in second-line treatments and beyond. Further studies are necessary to identify prognostic and predictive biomarkers in osteosarcomas.

References

1. Raymond, A.K.; Jaffe, N. Osteosarcoma multidisciplinary approach to the management from the pathologist's perspective. Pediatr. Adolesc. Osteosarcoma 2009, 152, 63–84.

2. Geller, D.S.; Gorlick, R. Osteosarcoma: A review of diagnosis, management, and treatment strategies. Clin. Adv. Hematol. Oncol. 2010, 8, 705–718.

3. Strauss, S.J.; Frezza, A.M.; Abecassis, N.; Bajpai, J.; Bauer, S.; Biagini, R.; Bielack, S.; Blay, J.Y.; Bolle, S.; Bonvalot, S.; et al. Bone sarcomas: ESMO-EURACAN-GENTURIS-ERN PaedCan Clinical Practice Guideline for diagnosis, treatment and follow-up. Ann. Oncol. 2021, 32, 1520–1536. [CrossRef]

4. Mirabello, L.; Troisi, R.J.; Savage, S.A. Osteosarcoma incidence and survival rates from 1973 to 2004: Data from the Surveillance, Epidemiology, and End Results Program. Cancer 2009, 115, 1531–1543. [CrossRef]

5. Bielack, S.S.; Kempf-Bielack, B.; Delling, G.; Exner, G.U.; Flege, S.; Helmke, K.; Kotz, R.; Salzer-Kuntschik, M.; Werner, M.; Winkelmann, W.; et al. Prognostic Factors in High-Grade Osteosarcoma of the Extremities or Trunk: An Analysis of 1,702 Patients Treated on Neoadjuvant Cooperative Osteosarcoma Study Group Protocols. J. Clin. Oncol. 2002, 20, 776–790. [CrossRef]

6. Gill, J.; Gorlick, R. Advancing therapy for osteosarcoma. Nat. Rev. Clin. Oncol. 2021, 18, 609–624. [CrossRef]

7. WHO. Soft Tissue and Bone Tumours, 5th ed.; Board CoTE, Ed.; WHO: Geneva, Switzerland, 2020.

8. Luetke, A.; Meyers, P.A.; Lewis, I.; Juergens, H. Osteosarcoma treatment—where do we stand? A state of the art review. Cancer Treat. Rev. 2014, 40, 523–532. [CrossRef]

9. Kempf-Bielack, B.; Bielack, S.S.; Jürgens, H.; Branscheid, D.; Berdel, W.E.; Exner, G.U.; Göbel, U.; Helmke, K.; Jundt, G.; Kabisch, H.; et al. Osteosarcoma Relapse After Combined Modality Therapy: An Analysis of Unselected Patients in the Cooperative Osteosarcoma Study Group (COSS). J. Clin. Oncol. 2005, 23, 559–568. [CrossRef]

10. Grimer, R.J.; Bielack, S.; Flege, S.; Cannon, S.R.; Foleras, G.; Andreeff, I.; Sokolov, T.; Taminiau, A.; Dominkus, M.; SanJulian, M.; et al. Periosteal

osteosarcoma—A European review of outcome. Eur. J. Cancer 2005, 41, 2806–2811. [CrossRef]

11. Marina, N.M.; Smeland, S.; Bielack, S.S.; Bernstein, M.; Jovic, G.; Krailo, M.D.; Hook, J.M.; Arndt, C.; van den Berg, H.; Brennan, B.; et al. Comparison of MAPIE versus MAP in patients with a poor response to preoperative chemotherapy for newly diagnosed high-grade osteosarcoma (EURAMOS-1): An open-label, international, randomised controlled trial. Lancet Oncol. 2016, 17, 1396–1408. [CrossRef]

12. Bielack, S.S.; Smeland, S.; Whelan, J.S.; Marina, N.; Jovic, G.; Hook, J.M.; Krailo, M.D.; Gebhardt, M.; Pápai, Z.; Meyer, J.; et al. Methotrexate, Doxorubicin, and Cisplatin (MAP) Plus Maintenance Pegylated Interferon Alfa-2b Versus MAP Alone in Patients With Resectable High-Grade Osteosarcoma and Good Histologic Response to Preoperative MAP: First Results of the EURAMOS-1 Good Response Randomized Controlled Trial. J. Clin. Oncol. 2015, 33, 2279–2287.

13. Palmerini, E.; Torricelli, E.; Cascinu, S.; Pierini, M.; De Paolis, M.; Donati, D.; Cesari, M.; Longhi, A.; Abate, M.; Paioli, A.; et al. Is there a role for chemotherapy after local relapse in high-grade osteosarcoma? Pediatr. Blood Cancer 2019, 66, e27792. [CrossRef]

14. Hodi, F.S.; Chiarion-Sileni, V.; Gonzalez, R.; Grob, J.J.; Rutkowski, P.; Cowey, C.L.; Lao, C.D.; Schadendorf, D.; Wagstaff, J.; Dummer, R.; et al. Nivolumab plus ipilimumab or nivolumab alone versus ipilimumab alone in advanced melanoma (CheckMate 067): 4-year outcomes of a multicentre, randomised, phase 3 trial. Lancet Oncol. 2018, 19, 1480–1492. [CrossRef]

15. Brahmer, J.R.; Rodriguez-Abreu, D.; Robinson, A.G.; Hui, R.; Csoszi, T.; Fulop, A.; Gottfried, M.; Peled, N.; Tafreshi, A.; Cuffe, S.; et al. Health-related quality-of-life results for pembrolizumab versus chemotherapy in advanced, PD-L1-positive NSCLC (KEYNOTE-024): A multicentre, international, randomised, open-label phase 3 trial. Lancet Oncol. 2017, 18, 1600–1609. [CrossRef]

16. Mok, T.S.K.; Wu, Y.L.; Kudaba, I.; Kowalski, D.M.; Cho, B.C.; Turna, H.Z.; Castro, G., Jr.; Srimuninnimit, V.; Laktionov, K.K.; Bondarenko, I.; et al. Pembrolizumab versus chemotherapy for previously untreated, PD-L1-expressing, locally advanced or

metastatic non-small-cell lung cancer (KEYNOTE-042): A randomised, open-label, controlled, phase 3 trial. Lancet 2019, 393, 1819–1830. [CrossRef]

17. Motzer, R.J.; Tannir, N.M.; McDermott, D.F.; Aren Frontera, O.; Melichar, B.; Choueiri, T.K.; Plimack, E.R.; Barthelemy, P.; Porta, C.; George, S.; et al. Nivolumab plus Ipilimumab versus Sunitinib in Advanced Renal-Cell Carcinoma. N. Engl. J. Med. 2018, 378, 1277–1290. [CrossRef]

18. Wedekind, M.F.; Wagner, L.M.; Cripe, T.P. Immunotherapy for osteosarcoma: Where do we go from here? Pediatr. Blood Cancer 2018, 65, e27227. [CrossRef]

19. Chen, C.; Xie, L.; Ren, T.; Huang, Y.; Xu, J.; Guo, W. Immunotherapy for osteosarcoma: Fundamental mechanism, rationale, and recent breakthroughs. Cancer Lett. 2021, 500, 1–10. [CrossRef]

20. Clemente, O.; Ottaiano, A.; Di Lorenzo, G.; Bracigliano, A.; Lamia, S.; Cannella, L.; Pizzolorusso, A.; Di Marzo, M.; Santorsola, M.; De Chiara, A.; et al. Is immunotherapy in the future of therapeutic management of sarcomas? J. Transl. Med. 2021, 19, 173.

21. Pilavaki, P.; Panagi, M.; Arifi, S.; Jones, R.L.; Stylianopoulos, T.; Constantinidou, A. Exploring the landscape of immunotherapy approaches in sarcomas. Front. Oncol. 2022, 12, 1069963. [CrossRef]

22. Tawbi, H.A.; Burgess, M.; Bolejack, V.; Van Tine, B.A.; Schuetze, S.M.; Hu, J.; D'Angelo, S.; Attia, S.; Riedel, R.F.; Priebat, D.A.; et al. Pembrolizumab in advanced soft-tissue sarcoma and bone sarcoma (SARC028): A multicentre, two-cohort, single-arm, open-label, phase 2 trial. Lancet Oncol. 2017, 18, 1493–1501. [CrossRef]

23. Le Cesne, A.; Marec-Berard, P.; Blay, J.Y.; Gaspar, N.; Bertucci, F.; Penel, N.; Bompas, E.; Cousin, S.; Toulmonde, M.; Bessede, A.; et al. Programmed cell death 1 (PD-1) targeting in patients with advanced osteosarcomas: Results from the PEMBROSARC study. Eur. J. Cancer 2019, 119, 151–157. [CrossRef]

24. D'Angelo, S.P.; Richards, A.L.; Conley, A.P.; Woo, H.J.; Dickson, M.A.; Gounder, M.; Kelly, C.; Keohan, M.L.; Movva, S.; Thornton, K.; et al. Pilot study of bempegaldesleukin in combination with nivolumab in patients with metastatic sarcoma. Nat. Commun. 2022, 13, 3477. [CrossRef]

25. Shi, J.; Li, M.; Yang, R. Tumor-infiltrating lymphocytes as a feasible adjuvant immunotherapy for osteosarcoma with a poor response to neoadjuvant chemotherapy. Immunotherapy 2020, 12, 641–652. [CrossRef]

26. Zhou, X.; Wu, J.; Duan, C.; Liu, Y. Retrospective Analysis of Adoptive TIL Therapy plus Anti-PD1 Therapy in Patients with Chemotherapy-Resistant Metastatic Osteosarcoma. J. Immunol. Res. 2020, 2020, 7890985. [CrossRef]

27. Wang, C.; Li, M.; Wei, R.; Wu, J. Adoptive transfer of TILs plus anti-PD1 therapy: An alternative combination therapy for treating metastatic osteosarcoma. J. Bone Oncol. 2020, 25, 100332. [CrossRef]

28. Ahmed, N.; Brawley, V.S.; Hegde, M.; Robertson, C.; Ghazi, A.; Gerken, C.; Liu, E.; Dakhova, O.; Ashoori, A.; Corder, A.; et al. Human Epidermal Growth Factor Receptor 2 (HER2)-Specific Chimeric Antigen Receptor-Modified T Cells for the Immunotherapy of HER2-Positive Sarcoma. J. Clin. Oncol. 2015, 33, 1688–1696. [CrossRef]